



Identification and Management of Ankyloglossia and Its Effect on Breastfeeding in Infants: Clinical Report

Jennifer Thomas, MD, MPH, FAAP,^a Maya Bunik, MD, MPH, FAAP,^b Alison Holmes, MD, MPH, FAAP,^c Martha Ann Keels, DDS, PhD,^d Brenda Poindexter, MD, MS, FAAP,^e Anna Meyer, MD, FAAP,^f Alison Gilliland, MD, FAAP,^g SECTION ON BREASTFEEDING, COUNCIL ON QUALITY IMPROVEMENT AND PATIENT SAFETY, SECTION ON ORAL HEALTH, COMMITTEE ON FETUS & NEWBORN, SECTION ON OTOLARYNGOLOGY-HEAD AND NECK SURGERY

Ankyloglossia refers to a congenitally tight lingual frenulum that limits the motion of the tongue. Whether the release of a tight lingual frenulum in neonates improves breastfeeding is not clear. Because many of the symptoms of ankyloglossia overlap those of other breastfeeding difficulties, a team partnership is necessary.

INTRODUCTION

The American Academy of Pediatrics (AAP) recommends exclusive breastfeeding for about 6 months, with continuation of breastfeeding for 2 years or longer as mutually desired by mother and infant.^{1*} The importance of breastfeeding is supported by the World Health Organization,² the Centers for Disease Control and Prevention,³ the American Academy of Pediatric Dentistry,⁴ the American Dental Association,⁵ and numerous other organizations. When breastfeeding problems arise, families look to health care professionals, including pediatricians and lactation specialists, for help. For the sake of nursing dyads searching for solutions to breastfeeding issues, a team approach is best.

DEFINITION

Ankyloglossia is a condition present at birth that restricts the tongue's range of motion because of a short or tight band of tissue called the

* The word chestfeeding may be used by transgender, nonbinary, and other parents to describe how they feed their infants. It may refer to human milk or human milk-substitute feeding, from a person who lactates or not. Health outcomes in published literature reflect breastfeeding and may not be applicable to chestfeeding. Because of this broad and variable definition, chestfeeding and breastfeeding are not always synonymous, and the words are not interchangeable. Throughout this document, the words breastfeeding and human milk will be used.

abstract

^aDepartment of Pediatrics, Advocate Aurora Health, Milwaukee, Wisconsin; ^bDepartment of Pediatrics, University of Colorado, School of Medicine, and Children's Hospital Colorado, Aurora, Colorado; ^cSection of Pediatric Hospital Medicine, Department of Pediatrics, Dartmouth Health Children's/Geisel School of Medicine, Lebanon, New Hampshire; ^dDepartment of Pediatrics, Duke University, and Division of Pediatric Dentistry and Public Health, Adams School of Dentistry, University of North Carolina-Chapel Hill, Chapel Hill, North Carolina; ^eDepartment of Pediatrics, Children's Healthcare of Atlanta and Emory University School of Medicine, Atlanta, Georgia; ^fDepartment of Pediatrics, University of California San Francisco School of Medicine, and University of California San Francisco Benioff Children's Hospital San Francisco, San Francisco, California; and ^gChildren's Medical Center, Denver, Colorado

Drs Thomas and Bunik conceptualized, drafted, and critically revised the manuscript; Drs Holmes, Keels, Poindexter, Meyer, and Gilliland drafted and critically revised the manuscript; and all authors approved the final manuscript as submitted and agree to be accountable for all aspects of the work.

This document is copyrighted and is property of the American Academy of Pediatrics and its Board of Directors. All authors have filed conflict of interest statements with the American Academy of Pediatrics. Any conflicts have been resolved through a process approved by the Board of Directors. The American Academy (continued)

To cite: Thomas J, Bunik M, Holmes A, et al; American Academy of Pediatrics, Section on Breastfeeding, Council on Quality Improvement and Patient Safety, Section on Oral Health, Committee on Fetus & Newborn, Section on Otolaryngology-Head and Neck Surgery. Identification and Management of Ankyloglossia and Its Effect on Breastfeeding in Infants: Clinical Report. *Pediatrics*. 2024;154(2):e2024067605

lingual frenulum, which tethers the bottom of the tongue's tip to the floor of the mouth. A restrictive lingual frenulum may interfere with breastfeeding by not allowing the infant to extend and elevate their tongue to grasp the nipple with suckling.

PROBLEM

There are no uniform accepted diagnostic criteria for the diagnosis of ankyloglossia. There is a lack of consensus for treatment of ankyloglossia, leading to wide practice variation in the United States and internationally.^{6–12} At the same time, the diagnosis of ankyloglossia and the frequency of performing a frenotomy has increased recently worldwide.^{7–12} Some medical practitioners and researchers are concerned that infants and children are being overdiagnosed with ankyloglossia.^{13–16} Two published systematic reviews of ankyloglossia and breastfeeding have noted no clear criteria for the diagnosis of ankyloglossia and a lack of good evaluation of treatments, including frenotomy, on breastfeeding outcomes.^{6,17} The Academy of Breastfeeding Medicine and the American Academy of Otolaryngology–Head and Neck Surgery (AAO-HNS) both released statements on ankyloglossia in breastfeeding dyads^{13,18} that summarize the issues associated with infant ankyloglossia. Based on research and information published in peer-reviewed journals, this AAP clinical report will present the currently available information on diagnosis and treatment of ankyloglossia and make expert recommendations to help pediatricians care for the breastfeeding infant.

ANATOMY OF ANKYLOGLOSSIA AND PHYSIOLOGY OF LACTATION

The embryologic development of tongue is a complicated process that starts around the fourth or fifth week of gestation, originating with the pharyngeal arches, and has key influence on shaping the oral cavity.¹⁹ Frenula are membranous folds of mucous membrane that attach one anatomic structure to another. Intraorally, there are several potential frenula: the lingual frenulum, the maxillary labial frenulum, and the buccal frenula. Frenula are defined in Text Box 1. Tight frenula can create constrictions between 2 structures (eg, tongue and gums), which can affect the movement and the function of these structures.

Anatomic work by Mills et al shows that the lingual frenulum is not a discrete band of tissue but a dynamic midline fold of a layer of fascia under the oral mucosa. The fold extends across the floor of the mouth and inserts in the inner arc of the mandible. When the tongue is elevated, a midline fold is formed. Branches of the lingual nerve and, in some infants, part of the genioglossus muscle were found located superficially in the fold created by the movement of the tongue. In infants, tongue movement partially depends on the length of the anterior

TEXT BOX 1

Definitions

- Symptomatic ankyloglossia – infant with physical examination consistent with a restrictive frenulum and difficulty with feeding whose difficulties are not improved with lactation support.
- Frenotomy, frenectomy, or frenulectomy – a surgical procedure to release a frenulum. The term frenotomy is used in this clinical report.

Locations of intraoral frenula

- Lingual frenulum – connects the underside of the tongue to the floor of the mouth.
- Maxillary labial frenulum – attaches the maxillary lip to the alveolar mucosa above the maxillary central incisors.
- Buccal frenula – connects the buccal mucosa to the alveolar mucosa in the posterior region of the maxilla and/or mandible.

tongue, the location of the frenulum insertions on the floor of the mouth, and the ventral tongue. The lingual frenulum appearance varies along a continuum from translucent to opaque. A translucent frenulum is a mucosal layer alone. An opaque frenulum consists of mucosa, fascia, and at times, the genioglossus muscle. The lingual frenulum does not connect to the posterior tongue (tongue base) (Fig 1).²⁰

Consequently, Mills et al suggest that the term “posterior tongue tie” is anatomically incorrect nomenclature and that its use should be discontinued. Mills et al assert that ankyloglossia cannot be diagnosed solely by the appearance of the lingual frenulum.^{20,21} The AAO-HNS, in its consensus statement, could not reach agreement on the definition of posterior ankyloglossia (Fig 2).¹³ With the finding of Mills et al that the band of tissue at the base of the tongue often contains the genioglossus muscle, this muscle may lengthen with use in feeding, and the infant's feeding abilities may improve with time.²²

Breastfeeding requires coordination of tongue elevation and extension. The tongue must aid in milk removal from the nipple and safely remove the milk bolus from the oral cavity. When an infant has adequate latch on the nipple, milk flow occurs because the anterior tongue lowers and creates an intraoral vacuum. As the tongue raises, the vacuum is decreased, and the milk bolus is transferred to the pharynx. The nipple elongates to the junction of the hard and soft palate, and is not distorted by tongue movement.²³

Anatomic variations of the lingual frenulum do not necessarily lead to difficulties with breastfeeding. Fewer than 50% of infants with physical findings consistent with ankyloglossia had difficulty breastfeeding.^{24–26} In this clinical report, the combination of a tight lingual frenulum and concomitant breastfeeding difficulties that do not improve with lactation support are referred to as “symptomatic ankyloglossia.”^{21,27,28} Other factors such as abnormal oral anatomy, infant suckling ability, and maternal breast anatomy also play roles in symptomatic ankyloglossia.

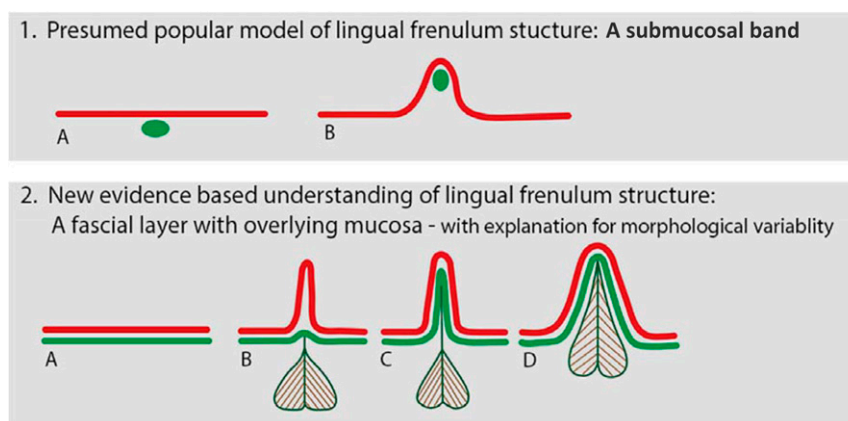


FIGURE 1

Anatomic-based diagram of lingual frenulum structure. Diagram illustrating coronal section of floor of mouth: (1) Current, presumed understanding of lingual frenulum structure: A submucosal band: (a) tongue relaxed, (b) tongue elevated, raising lingual frenulum. Red line: Oral mucosa. Green oval: Coronal section of connective tissue band. (2) Our newly proposed anatomically based understanding of lingual frenulum structure: Red line: Oral mucosa, green line: Floor of mouth fascia, with genioglossus suspended from fascia. (a) Tongue relaxed, floor of mouth fascia immediately beneath mucosa. (b–d) Variations in frenulum morphology with tongue elevated to raise frenulum. (b) Transparent frenulum: Mucosal fold elevates above fascia to form fold, with fascia remaining low/at base of fold. (c) Opaque frenulum: mucosal and fascia elevate together to form fold. (d) Thick frenulum: Mucosa and fascia elevate together, with genioglossus also drawn into fold.²⁰ [Color figure can be viewed at wileyonlinelibrary.com] Image credit: Mills N, Pransky SM, Geddes DT, Mirjalili SA. What is a tongue tie? Defining the anatomy of the in-situ-lingual frenulum. *Clin Anat*. 2019;32:749–761. Clinical Anatomy published by Wiley Periodicals, Inc. on behalf of American Association of Clinical Anatomists. Used under the terms of the Creative Commons Attribution License.

EPIDEMIOLOGY

Three different studies focused on ankyloglossia diagnoses in the United States, Canada, and England found that its frequency of diagnosis in neonates ranges from 1.7% to 10.7%.^{24–26} Walsh and Benoit¹⁵ and Wei et al¹² used inpatient hospital databases to evaluate incidence of ankyloglossia diagnoses and performance of lingual frenotomies over time in the United States. They reported an almost 10-fold increase in the diagnosis of ankyloglossia between 1997 and 2012, and a further doubling between 2012 and 2016. Rates of performance of frenotomy also increased 10-fold between 1997 and 2012 and doubled between 2012 and 2014 (Figs 3

and 4). Compared with the general population, children with ankyloglossia or frenotomy were more often male, privately insured, and from higher median-income zip codes, and varied by geographic region. Other demographic or socioeconomic factors have not been studied to date. Similar trends of markedly increased rates of diagnosis and treatment, as well as geographic variation, have been reported in Canada,^{8,9} Australia,¹⁰ and Denmark.¹¹ These significant increases in the incidence of ankyloglossia diagnoses and the rates of frenotomy performance may be attributable to true increased incidence, improved diagnostic accuracy, or overdiagnosis.

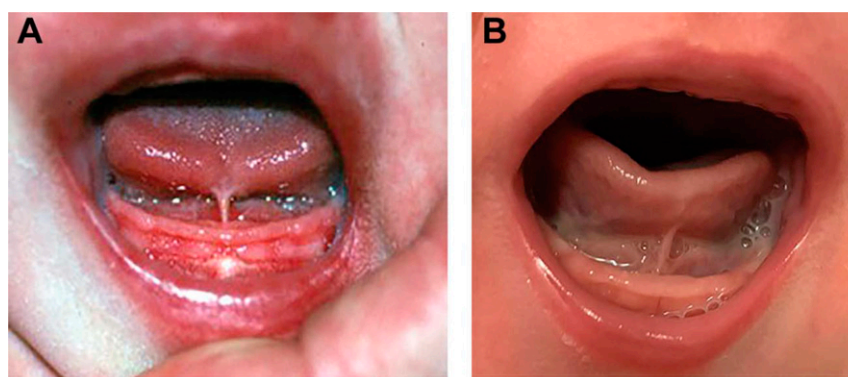


FIGURE 2

(A) An example of anterior ankyloglossia with the lingual frenulum attaching at the tongue tip, limiting tongue mobility. (B) Posterior attachment of lingual frenulum. In the AAO-HNS consensus statement, consensus was not reached regarding the definition of posterior ankyloglossia. Some in the consensus group would describe this figure as an example of posterior ankyloglossia if there are objective findings of restricted tongue mobility caused by the lingual frenulum.¹³ Images used with permission from Messner AH, Walsh J, Rosenfeld RM, Schwartz SR, Ishman SL, Baldassari C. Clinical consensus statement: ankyloglossia in children. *Otolaryngol Head Neck Surg*. 2020;162(5):597–611.

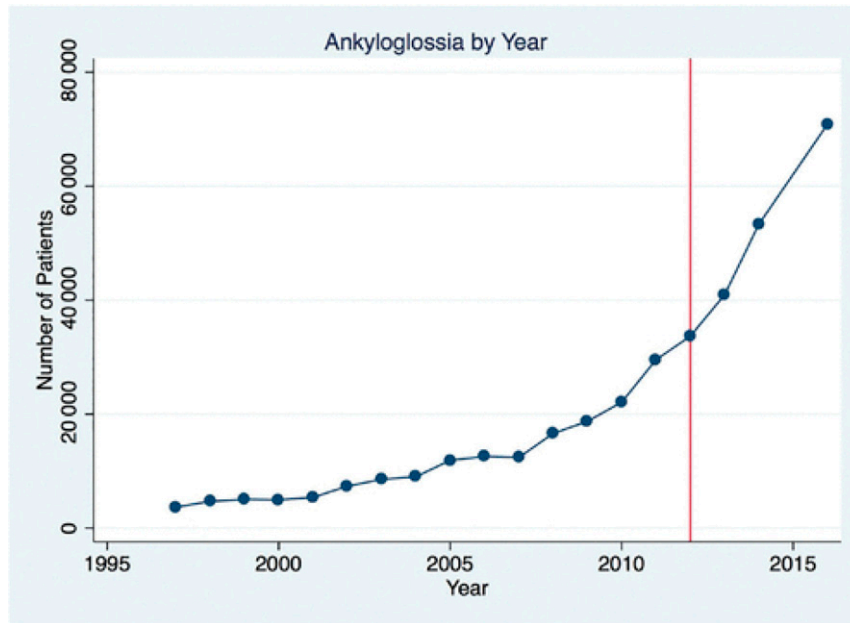


FIGURE 3

Number of inpatient newborn ankyloglossia diagnoses in United States by year.¹² Image used with permission from Wei EX, Tunkel D, Boss E, Walsh J. Ankyloglossia: update on trends in diagnosis and management in the United States, 2012–2016. *Otolaryngol Head Neck Surg*. 2020;163(5):1029–1031.

ASSESSMENT OF SYMPTOMATIC ANKYLOGLOSSIA: MATERNAL PAIN, POOR LATCH, AND POOR MILK TRANSFER

Symptomatic ankyloglossia is defined as a restrictive lingual frenulum that causes problems with breastfeeding that are not improved with lactation support (Text Box 1). Breastfeeding difficulties are common in the postpartum

period. Nipple pain and a poor or ineffective latch are among the most common complaints of breastfeeding mothers.^{29–32}

However, most breastfeeding difficulty is not related to symptomatic ankyloglossia. Breastfeeding difficulty as it relates to ankyloglossia has not been uniformly defined, but several retrospective or nonrandomized

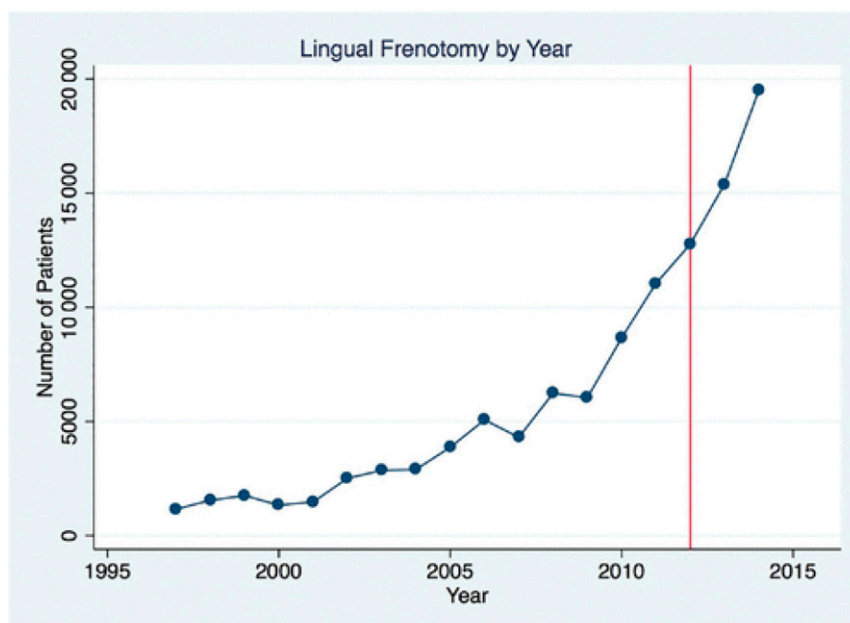


FIGURE 4

Number of inpatient infant frenotomies in United States by year.¹² Image used with permission from Wei EX, Tunkel D, Boss E, Walsh J. Ankyloglossia: update on trends in diagnosis and management in the United States, 2012–2016. *Otolaryngol Head Neck Surg*. 2020;163(5):1029–1031.

studies and case reports have identified increased incidence of maternal nipple pain,^{26,33} poor infant latch,²⁶ inadequate infant weight gain,^{23,34} and neonatal hypernatremic dehydration³⁵ in infants with ankyloglossia when compared with other breastfeeding neonates. Nipple pain alone as a marker of symptomatic ankyloglossia is insufficient, because between 34% and 96% of breastfeeding mothers experience nipple pain in the immediate postpartum period.³⁶ Timing or persistence of symptoms may be important, because most nipple pain peaks at about 3 days postpartum and decreases to mild levels for most women within 7 to 10 days.³⁶ A thorough feeding evaluation is described below.

PEDIATRICIAN'S ROLE IN DIAGNOSING ANKYLOGLOSSIA

The partnering of pediatricians and lactation specialists together for the sake of the nursing dyad is important and outlined in the algorithm below (Fig 5). A pediatrician considering the diagnosis of ankyloglossia leading to breastfeeding difficulty, especially with insufficient growth, should start with the differential diagnosis of poor weight gain and ineffective latch. Important aspects to review may include:

- A review of the prenatal course, including intrapartum and postpartum medications, breastfeeding history, breast surgeries, breast and nipple anatomy, and family history
- Infant feeding history including any abnormal features (coughing, choking, color change, bilious emesis, early tiring) and/or breastfeeding difficulties (nipple pain, nipple trauma, long feeding times, difficulty staying attached to the breast)

Perform a complete infant physical examination with special attention to:

- Visual inspection of the face, jaw, neck, and oropharynx
- Atypical features including dysmorphic features, micrognathia, retrognathia, and cleft lip and/or palate
- Assessment of tongue movement and coordination with a clean, gloved finger in the mouth to test the suck reflex and to palpate the hard and soft palate
- Appearance of lingual frenulum, including the inability of the infant to extend tongue over the lower alveolar ridge or lift tongue midway to the palate, or a heart-shaped tongue on extension
- Assessment of milk transfer using pre- and postfeeding weights, observation of a feeding session, and assessment of weight gain using World Health Organization growth standards.^{37,38}

The differential diagnosis of ineffective feeding or poor growth includes infection, congenital heart disease, congenital adrenal hyperplasia, inborn errors of metabolism, and

intestinal obstruction. Pediatricians need to work with pediatric nurses in their practice or refer to lactation professionals to assess latch and breastfeeding using a standardized tool such as the Latch, Audible Swallowing, Type of Nipple, Comfort, and Hold assessment score³⁹ or Infant Breastfeeding Assessment Tool.⁴⁰ If a dentist is consulted, the dentist can also collaborate with the team defined above, including the infant's primary health care provider. As always, a team approach to this issue is best.

TOOLS FOR EVALUATION OF ANKYLOGLOSSIA

Numerous tools for assessing the severity of ankyloglossia have been published in peer-reviewed journals and encourage formal scoring of the observed tongue movement (Table 1). These screening tools include: the Hazelbaker Assessment Tool for Lingual Frenulum Function, the shortened form of the Assessment Tool for Lingual Frenulum Function, the Frenotomy Decision Tool for Breastfeeding Dyads, the Bristol Tongue Assessment Tool, the Neonatal Tongue Screening Test, and Kotlow's grading system.^{41–46}

Unfortunately, none of the tools have been validated. The Agency for Healthcare Research and Quality reported that a standardized approach to identifying and classifying ankyloglossia and a good description of the natural history of ankyloglossia by severity, including long-term risk of feeding problems, are needed.⁶

TREATMENTS FOR SYMPTOMATIC ANKYLOGLOSSIA

As with any procedure performed on an infant, it is important to obtain and document informed consent, which includes explaining information such as alternatives (waiting/observation/revisiting lactation specialist), risks of bleeding and infection, pain control, and postprocedure care.

Historically and currently, the most common approach to infant frenotomy is scissor clipping of the frenulum, with or without previous clamping. Fingers, a grooved retractor, or cotton-tipped applicators can be used to retract the tongue. Typical blunt-tip scissors technique has not been reported to have complications^{17,47} and usually does not require anesthetic or sutures in the newborn infant.

Recently, there has been a marked increase in the use of laser for frenotomy by physicians, oral surgeons, and dentists.⁴⁸ There are no comparative data on the use of laser versus clipping for frenotomy in infants younger than 6 months that support routine use. The AAO-HNS reached a consensus that "there is insufficient evidence to support claims that one technique of frenotomy, such as laser, is superior to other techniques."¹³

Other treatments supported by some health care professionals include physical therapy, craniosacral therapy, or myofascial therapies.⁴⁹ These treatments also are not well-studied and often require out-of-pocket costs for families. Postfrenotomy stretching exercises in which the parents open

Ankyloglossia Algorithm

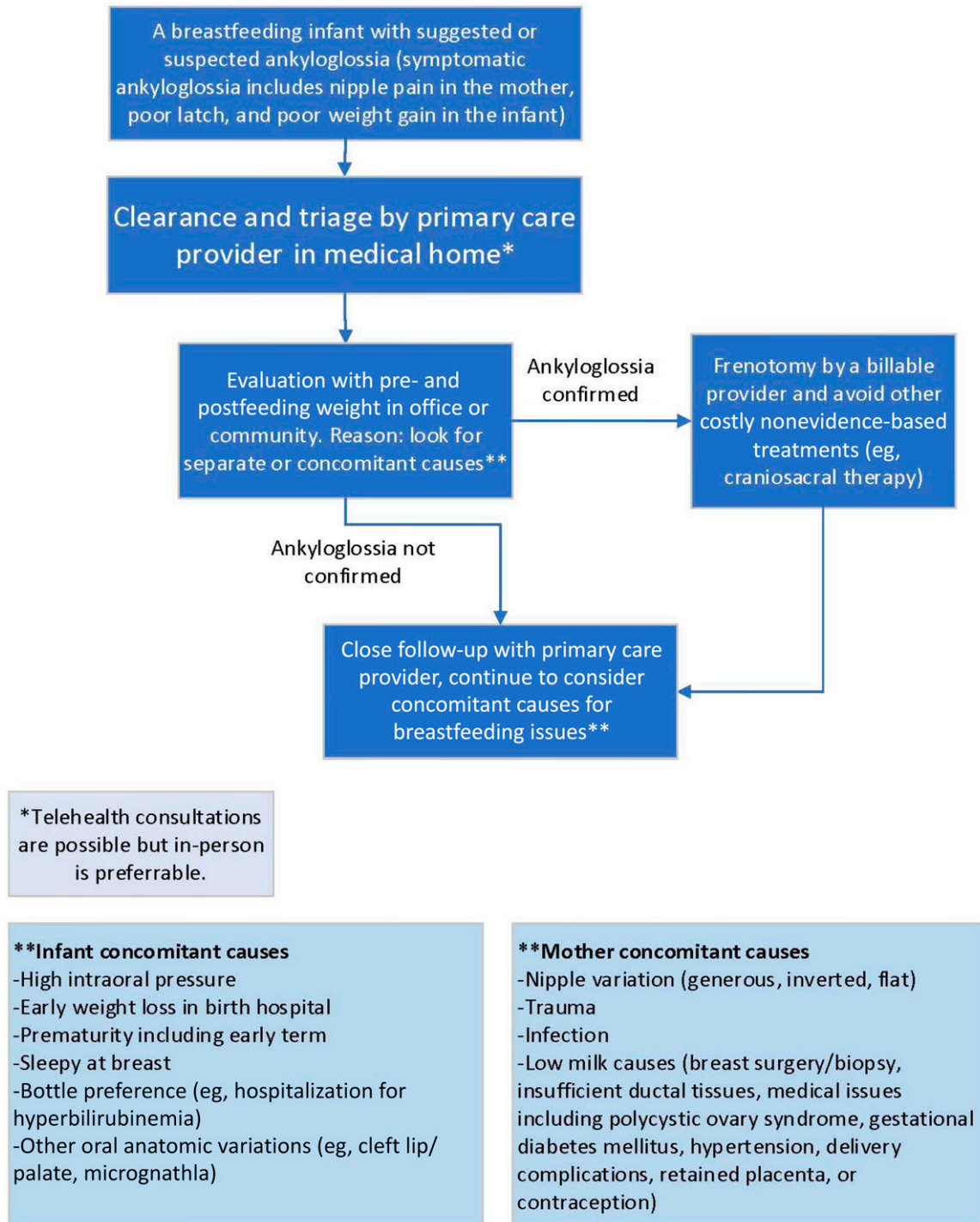


FIGURE 5

Ankyloglossia algorithm. Created by: Maya Bunik, MD, MPH, FAAP.

the wound several times to prevent reattachment are not recommended and may cause oral aversion.^{50,51} Although osteopathic manipulation treatment has been shown to be

helpful for latching problems in breastfeeding newborns,⁵² there is no research looking specifically at its role in helping with breastfeeding problems related to ankyloglossia.

TABLE 1 Summary of Scoring Systems for Assessment of Ankyloglossia and Reliability and Validity Data

Source	Scoring System	Anatomic Versus Functional	Interrater Reliability	Validity	Used in Other Published Studies
Kotlow 2011 ⁴⁸	Based on insertion of lingual frenulum from the tip of the tongue Class 1: Frenulum inserts 0–3 mm from tip of tongue Class 2: Frenulum inserts 4–6 mm from tip of tongue Class 3: Frenulum inserts 7–9 mm from tip of tongue Class 4: Frenulum inserts 10–12 mm from tip of tongue or submucosally	Anatomic	No	No	—
ATLFF (Hazelbaker 2010 ⁴¹)	Anatomic factors: Shape of tongue when lifted, length and elasticity of frenulum, and attachment of frenulum to inferior alveolar ridge Functional factors: Lateralization of tongue, cupping of the tongue, lift of tongue, peristalsis of tongue, extension of tongue, and snap-back of the tongue	Anatomic and functional	Moderate (kappa = 0.44) (Madlon 2006 ⁶⁸) Anatomic items (kappa = 0.4–0.6) Function items of tongue cupping, peristalsis, snap-back and spread low (kappa <0.05) Lateralization, lift, and tongue extension (kappa >0.65), agreement on recommendation for frenotomy (kappa = 0.92) (Amir 2006 ⁴²)	No	Madlon 2006, ⁶⁸ Rickie 2005, ⁶⁸ Amir 2006 ⁴³
Shortened ATLFF (Amir 2006 ⁴²)	Recommended shortened form of ATLFF using anatomic factors and functional factors of lateralization, lift, and extension of tongue	Anatomic and functional	(kappa of 0.4–0.6) for anatomy items Lateralization, lift, and tongue extension (kappa >0.65), agreement on recommendation for frenotomy (kappa = 0.92) (Amir 2006 ⁴²)	No	Emond 2014, ⁵⁵ Ingram 2015 ⁴³
Frenotomy Decision Tool for Breastfeeding Dyads (Srinivasin 2019 ⁴⁸)	Infant scored on inability to maintain latch, endless feeds, poor milk transfer and poor weight gain, and anatomic findings of inability to rest tongue on roof of the mouth, cup tongue, or maintain suction on finger or breast, diminished lateral tongue movement, and to protrude tongue past the gum line	Anatomic and functional	No	No	—
Bristol tongue Assessment Tool (Ingram 2015 ⁴³)	Tongue tip appearance: 0–2 Location of frenulum attachment to gum/ridge or floor of mouth: 0–2 Lift of tongue while crying: 0–2 Protrusion of tongue: 0–2	Anatomic and functional	Cronbach's α of 0.708	No	—
Neonatal Tongue Screening Test (de Andrada Fraga 2020, ²⁷ Martinelli 2012, ⁴⁴ de Almeida 2018 ⁶⁹)	Tongue and lip appearance at rest and crying, evaluation of frenulum Max score 12, >7 is altered lingual frenulum	Anatomic and functional	Intraclass correlation coefficient = 0.77 (95% CI, 0.64–0.89) (de Almeida 2018 ⁶⁹)	No	de Andrada Fraga 2020 ²⁷

ATLFF, Assessment Tool for Lingual Frenulum Function; CI, confidence interval.

RESEARCH CHALLENGES

There are several small, randomized trials of frenotomy. Recent reviews of these trials have concluded that these studies have not answered the question of whether frenotomy in infants with feeding difficulties results in longer-term breastfeeding success and resolution of maternal pain. Both reviews suggest that frenotomy causes a short-term reduction in nipple pain among breastfeeding mothers and an inconsistent positive effect on infant breastfeeding.^{17,47} Because breastfeeding pain is one of the most common reasons for early breastfeeding cessation,²⁹ decreasing pain is an important outcome of frenotomy to achieve continued breastfeeding. Because of the small number of studies and the high incidence of methodologic issues, including a lack of well-conducted randomized trials examining breastfeeding duration or exclusivity, definitive breastfeeding benefit has not been shown.^{17,47}

The only methodologically acceptable way to assess the efficacy of frenotomy on breastfeeding outcomes is through appropriately powered, blinded, randomized controlled trials with an appropriate follow-up period and sufficient breastfeeding support to the control group. The most significant problem with this group of studies is that none followed the control group in its natural state (with unaltered ankyloglossia) beyond 2 weeks of age, which is inadequate to assess improvement over time. All control infants were subject to frenotomy anywhere from later in the same day as the intervention group to, at the very latest, 2 weeks after the procedure was performed in the intervention group.^{24,53–56}

The maxillary labial frenulum, a normal oral structure present in all infants, has also recently been implicated in breastfeeding issues. Some researchers suggest correction of the maxillary labial frenulum for children with thick, short, or prominent maxillary labial frenula and breastfeeding issues, proposing that a tight band can limit the ability to have an adequate latch because of an inability to fully flange the upper lip.⁴⁵ Kotlow has described an unvalidated four-type grading system.⁴⁵ Santa Maria et al evaluated the Kotlow grading system by having several examiners examine a cohort of neonates and found both poor intrarater and interrater reliability.⁵⁷ They scored greater than 80% of all newborn infants as having highest grade of maxillary labial frenulum. The high incidence would suggest that this visual grading system is not a valid indicator of the impact of the maxillary labial frenulum on breastfeeding.⁵⁷ In addition to diagnoses made by the grading system and poor lip flanging, lip dimpling, blanching of the maxillary labial frenulum with elevation, bony remodeling of the alveolar ridge, and gastroesophageal reflux have been proposed as signs of a tight maxillary labial frenulum,⁵⁸ but lack supporting evidence in the peer-reviewed literature.

Several observational cohort studies^{58–60} have attempted to evaluate the release of the maxillary labial frenulum. All studies have included patients who simultaneously underwent lingual frenotomy. These studies were severely limited because

of the lack of a control group in a population that has a high propensity for improvement over time, the lack of a validated tool to measure the effect of maxillary labial frenulum on breastfeeding, and the performance of 2 simultaneous procedures in study participants, which negates any ability to determine the potential effect of maxillary labial frenotomy on breastfeeding. No randomized controlled trials of labial maxillary frenulum release have been performed to evaluate any of the functional or observational measures and the proposed impact of maxillary labial frenulum on breastfeeding. Concern has been noted in the literature that performing unnecessary procedures may have monetary influence.⁶¹ A Google search on August 11, 2023, showed that practitioners are asking for several hundred dollars to perform frenotomy, but parents are not made aware that an alternative, such as an otolaryngology visit, is covered by both Medicaid and commercial insurance.

Shah et al found no correlation between the appearance of the maxillary labial frenulum and breastfeeding problems, and no relationship between the appearance of the maxillary labial frenulum and ankyloglossia.⁶² Messner et al concluded that infants normally have an upper lip frenulum, the upper lip frenulum is not well defined, and its relationship to breastfeeding problems is unclear, and maxillary lip ties may be being overdiagnosed in some areas.¹³

Buccal frenula are also being released by some physicians and dentists to help with breastfeeding. There are no known physiologic reasons, published reports, or consensus among experts as to how buccal tie is defined or how it might impact breastfeeding. The AAO-HNS reached consensus that “surgery to release a buccal tie should not be performed.”¹³ The Academy of Breastfeeding Medicine statement reports that there is no evidence for surgically treating maxillary or buccal frenula.¹⁸

INTERNET AND SOCIAL MEDIA

The Internet and social media have contributed to the increase in awareness of ankyloglossia and use of frenotomy. Information online contains varying levels of accurate information including evidence from reliable health care organizations, but also personal testimonies, blogs, targeted advertising of frenotomy services, and misinformation related to frenotomy. For example, the normal newborn finding of sucking blisters is often used as a sign of tethered oral tissues.⁶³ Pediatricians should be aware of the concerns of parents who may have arrived at their own diagnosis from social media.⁶⁴ Parents may have trouble determining which information is reliable and unbiased. They may need help from their pediatrician to make a good decision about their infant’s breastfeeding issues and possible ankyloglossia.

COST

Frenotomies can be covered under both medical and dental insurance. Most infants are covered by a medical insurance policy soon after birth, either private insurance or Medicaid. In some states, Medicaid may cover a frenotomy, and some may require previous approval.

CONCLUSIONS AND RECOMMENDATIONS

1. Ankyloglossia is a variation of a normal oral structure. Symptomatic ankyloglossia is defined as a restrictive lingual frenulum that causes problems with breastfeeding that are not improved with lactation support. Infants with ankyloglossia and normal feeding patterns need no intervention. Frenotomy for other problems or to prevent issues such as speech articulation or obstructive sleep apnea in the future is not evidence based.¹⁸
2. Posterior ankyloglossia is a poorly defined term, lacking agreement from experts, and should not be used as a reason to perform surgical intervention on an infant.
3. Labial and buccal frenae are normal oral structures unrelated to breastfeeding mechanics and do not require surgical intervention to improve breastfeeding. Sucking blisters are a normal finding in newborn infants, and as such, are not suggestive of pathology.
4. Suboptimal breastfeeding is a complex issue and every nursing dyad with painful or ineffective feeding should have a complete breastfeeding assessment before any treatment is offered.^{65,66} Here, multidisciplinary communication and management between lactation specialists, feeding therapists, surgeons, and pediatricians are paramount for the best outcome for the family.
5. Newborn infants with possible symptomatic ankyloglossia need close monitoring, support of breastfeeding while in the hospital, early postdischarge follow-up, and monitoring of weight gain in their medical home.
6. Surgical intervention for symptomatic ankyloglossia, versus laser, can reasonably be offered after other causes of breastfeeding problems have been evaluated and treated. Frenotomy may decrease maternal nipple pain.^{6,17,67} Although the evidence is not strong, addressing pain is important for successful continued breastfeeding.
7. Frenotomy should be performed by a trained professional, either the medical home provider or another to whom the medical home refers the patient. The performing professional should be experienced in the medical care of newborns and older infants and should maintain needed privileges for the procedure. As with any surgical procedure, before performing a frenotomy, the performing provider should take a “time out” to:
 - a. Obtain a signed consentb
 - b. Discuss alternatives, risks, and benefits of the procedurec
 - c. Discuss and provide pain control optionsd
 - d. Document previous receipt of intramuscular vitamin Ke
 - e. Provide information on postsurgical care and follow-up
8. Attention to prevention of surgical complications, hemorrhage risk, pain mitigation, and evidence-based postsurgical care is recommended. Postoperative stretching exercises are not evidence-based and are not recommended.
9. Further research including a standardized approach to identifying and classifying ankyloglossia, long-term outcome measures, and a good description of the natural history of ankyloglossia by severity, including long-term risk of feeding problems, is needed.

LEAD AUTHORS

Jennifer Thomas, MD, MPH, FAAP
Maya Bunik, MD, MPH, FAAP
Alison Holmes, MD, MPH, FAAP
Martha Ann Keels, DDS, PhD
Brenda Poindexter, MD, MS, FAAP
Anna Meyer, MD, FAAP
Alison Gilliland, MD, FAAP

SECTION ON BREASTFEEDING EXECUTIVE COMMITTEE, 2022–2023

Maya Bunik, MD, MSPH, FAAP, FABM, Chairperson
Sahira Long, MD, IBCLC, FAAP, FABM
Monica Richter, MD, PhD, IBCLC, FAAP, FABM
Emily Hannon, MD, IBCLC, FAAP
Ann Kellams, MD, IBCLC, FAAP, FABM
Tara Williams, MD, FAAP, FABM
Lori Feldman-Winter, MD, MPH, FAAP, FABM, Immediate Past Chairperson

SECTION ON BREASTFEEDING SUBCOMMITTEE CHAIRPERSONS AND LIAISONS

Sharon Mass, MD, FACOG – *American College of Obstetricians and Gynecologists* Liaison
Larry Noble, MD, FAAP, FABM
Rose St. Fleur, MD, FAAP, FABM, IBCLC
Lisa Stellwagen, MD, FAAP
Jennifer Thomas, MD, MPH, IBCLC, FAAP, FABM
Joan Younger Meek, MD, MS, RD, FAAP, FABM, IBCLC

SECTION ON BREASTFEEDING PAST CONTRIBUTING EXECUTIVE COMMITTEE MEMBERS

Mary O'Connor, MD, MPH, FAAP
Julie Ware, MD, MPH, FAAP, FABM, IBCLC

SECTION ON BREASTFEEDING STAFF

Kera Beskin, MPH, MBA
Ngozi Onyema-Melton, MPH, CHES

SECTION ON ORAL HEALTH EXECUTIVE COMMITTEE, 2022–2023

Jeffrey M. Karp, DMD, MS, Chairperson
Eric Beyer, MD, FAAP
Chevon Brooks, MD, FAAP
C. Eve Kimball, MD, FAAP
Anupama Rao Tate, DMD, MPH
Lauren Feldman, DMD, MPH

SECTION ON ORAL HEALTH LIAISONS

Matt Zaborowski, MPH, CPH – *American Dental Association*
Matt Crespino, MPH, RDH – *American Dental Hygienists' Association*

Amr Moursi, DDS, PhD – *American Academy of Pediatric Dentistry*

SECTION ON ORAL HEALTH STAFF

Kera Beskin, MPH, MBA

COUNCIL ON QUALITY IMPROVEMENT AND PATIENT SAFETY, 2022–2023

Ulfat Shaikh, MD, FAAP, Chairperson
Francisco Javier Alvarez, MD, FAAP
John Chuo, MD, FAAP
Meghan Drayton Jackson, DO, FAAP
Julia M. Kim, MD, FAAP
Mary Beth Miotto, MD, FAAP
Raina Paul, MD, FAAP
Corinna Rea, MD, FAAP
Sandra Spencer, MD, FAAP
Amy Tyler, MD, FAAP
Joyee Vachani, MD, FAAP

STAFF

Cathleen Guch, MPH

COMMITTEE ON FETUS AND NEWBORN, 2022–2023

Eric Eichenwald, MD, Chairperson
Namasivayam Ambalavanan, MD
Charleta Guillory, MD
Mark Hudak, MD
David Kaufman, MD
Camilia Martin, MD
Ashley Lucke, MD
Margaret Parker, MD
Arun Pramanik, MD
Kelly Wade, MD

LIAISONS

Timothy Jancelewicz, MD – *AAP Section on Surgery*

Michael Narvey, MD – *Canadian Pediatric Society*
Russell Miller, MD – *American College of Obstetricians and Gynecologists*
RADM Wanda Barfield, MD, MPH – *Centers for Disease Control and Prevention*
Lisa Grisham, APRN, NNP-BC – *National Association of Neonatal Nurses*

STAFF

Jim Couto, MA

SECTION ON OTOLARYNGOLOGY EXECUTIVE COMMITTEE 2022–2023

Jeffrey Philip Simons, MD, FAAP, Chairperson
Steven E. Sobol, MD, FAAP
Kavita Dedhia, MD, FAAP
Thomas Gallagher, DO, FAAP
Peggy Elaine Kelley, MD, FAAP
Pamela Anne Mudd, MD, MBA, FAAP
Samuel Ostrower, MD, FAAP
Eileen Margolies Raynor, MD, FAAP
Brian Kip Reilly MD, FAAP
Alanna Windsor, MD, FAAP

STAFF

Vivian B. Thorne

ACKNOWLEDGMENT

We thank Dr Mary O'Connor for her contributions to the development of this clinical report.

ABBREVIATIONS

AAO-HNS: American Academy of Otolaryngology–Head and Neck Surgery
AAP: American Academy of Pediatrics

of Pediatrics has neither solicited nor accepted any commercial involvement in the development of the content of this publication.

Clinical reports from the American Academy of Pediatrics benefit from expertise and resources of liaisons and internal (AAP) and external reviewers. However, policy statements from the American Academy of Pediatrics may not reflect the views of the liaisons or the organizations or government agencies that they represent.

The guidance in this report does not indicate an exclusive course of treatment or serve as a standard of medical care. Variations, considering individual circumstances, may be appropriate.

All clinical reports from the American Academy of Pediatrics automatically expire 5 years after publication unless reaffirmed, revised, or retired at or before that time.

DOI: <https://doi.org/10.1542/peds.2024-067605>

Address correspondence to Jennifer Thomas, MD, MPH. E-mail: drjen4kids@gmail.com

PEDIATRICS (ISSN Numbers: Print, 0031-4005; Online, 1098-4275).

Copyright © 2024 by the American Academy of Pediatrics

FUNDING: No external funding.

FINANCIAL/CONFLICT OF INTEREST DISCLOSURE: The authors have indicated they have no potential conflicts of interest to disclose.

REFERENCES

- Meek JY, Noble L; Section on Breastfeeding. Policy statement. Breastfeeding and the use of human milk. *Pediatrics*. 2022;150(1):e2022057988
- World Health Organization. Breastfeeding recommendations. Available at: https://www.who.int/health-topics/breastfeeding#tab=tab_2. Accessed May 17, 2022
- Centers for Disease Control and Prevention. Nutrition. Breastfeeding: recommendations and benefits. Available at: <https://www.cdc.gov/nutrition/infantandtoddlernutrition/breastfeeding/recommendations-benefits.html>. Accessed May 17, 2022
- American Academy of Pediatric Dentistry. Policy on dietary recommendations for infants, children, and adolescents. Available at: https://www.aapd.org/media/Policies_Guidelines/P_RecDietary.pdf. Accessed May 17, 2022
- American Dental Association. Breastfeeding: six things nursing moms should know about dental health. Available at: <https://www.mouthhealthy.org/en/az-topics/b/breastfeeding>. Accessed May 17, 2022
- Francis DO, Chinnadurai S, Morad A, et al. Agency for Healthcare Research and Quality. Treatments for ankyloglossia and ankyloglossia with concomitant lip-tie. Available at: www.effectivehealthcare.ahrq.gov/reports/final.cfm. Accessed May 9, 2022
- Walsh J, Links A, Boss E, Tunkel D. Ankyloglossia and lingual frenotomy: national trends in inpatient diagnosis and management in the United States, 1997–2012. *Otolaryngol Head Neck Surg*. 2017;156(4):735–740
- Lisonek M, Liu S, Dzakupas S, Moore AM, Joseph KS. Canadian Perinatal Surveillance System (Public Health Agency of Canada). Changes in the incidence and surgical treatment of ankyloglossia in Canada. *Paediatr Child Health*. 2017;22(7):382–386
- Joseph KS, Kinniburgh B, Metcalfe A, Razaz N, Sabr Y, Lisonkova S. Temporal trends in ankyloglossia and frenotomy in British Columbia, Canada, 2004–2013: a population-based study. *CMAJ Open*. 2016;4(1):E33–E40
- Kapoor V, Douglas PS, Hill PS, Walsh LJ, Tennant M. Frenotomy for tongue-tie in Australian children, 2006–2016: an increasing problem. *Med J Aust*. 2018;208(2):88–89
- Ellehauge E, Jensen JS, Grønhøj C, Hjuler T. Trends of ankyloglossia and lingual frenotomy in hospital settings among children in Denmark. *Dan Med J*. 2020;67(5):A01200051
- Wei EX, Tunkel D, Boss E, Walsh J. Ankyloglossia: update on trends in diagnosis and management in the United States, 2012–2016. *Otolaryngol Head Neck Surg*. 2020;163(5):1029–1031
- Messner AH, Walsh J, Rosenfeld RM, et al. Clinical consensus statement: ankyloglossia in children. *Otolaryngol Head Neck Surg*. 2020;162(5):597–611
- Hale M, Mills N, Edmonds L, et al. Complications following frenotomy for ankyloglossia: a 24-month prospective New Zealand pediatric surveillance unit study. *J Paediatr Child Health*. 2020;56(4):557–562
- Walsh J, McKenna Benoit M. Ankyloglossia and other oral ties. *Otolaryngol Clin North Am*. 2019;52(5):795–811
- Coon ER, Quinonez RA, Moyer VA, Schroeder AR. Overdiagnosis: how our compulsion for diagnosis may be harming children. *Pediatrics*. 2014;134(5):1013–1023
- O'Shea JE, Foster JP, O'Donnell CP, et al. Frenotomy for tongue-tie in newborn infants. *Cochrane Database Syst Rev*. 2017;3(3):CD011065
- LeFort Y, Evans A, Livingstone V, et al. Academy of Breastfeeding Medicine. Academy of Breastfeeding Medicine position statement on ankyloglossia in breastfeeding dyads. *Breastfeed Med*. 2021;16(4):278–281
- Jain P, Rathee M. Embryology, tongue. In: *StatPearls*. StatPearls Publishing; 2021
- Mills N, Pransky SM, Geddes DT, Mirjalili SA. What is a tongue tie? Defining the anatomy of the in-situ lingual frenulum. *Clin Anat*. 2019;32(6):749–761
- Mills N, Keough N, Geddes DT, Pransky SM, Mirjalili SA. Defining the anatomy of the neonatal lingual frenulum. *Clin Anat*. 2019;32(6):824–835
- Walker RD, Messing S, Rosen-Carole C, McKenna Benoit M. Defining tip-frenulum length for ankyloglossia and its impact on breastfeeding: a prospective cohort study. *Breastfeed Med*. 2018;13(3):204–210
- Geddes DT, Langton DB, Gollow I, Jacobs LA, Hartmann PE, Simmer K. Frenulotomy for breastfeeding infants with ankyloglossia: effect on milk removal and sucking mechanism as imaged by ultrasound. *Pediatrics*. 2008;122(1):e188–e194
- Hogan M, Westcott C, Griffiths M. Randomized, controlled trial of division of tongue-tie in infants with feeding problems. *J Paediatr Child Health*. 2005;41(5-6):246–250
- Srinivasan A, Dobrich C, Mitnick H, Feldman P. Ankyloglossia in breastfeeding infants: the effect of frenotomy on maternal nipple pain and latch. *Breastfeed Med*. 2006;1(4):216–224
- Messner AH, Lalakea ML, Aby J, Macmahon J, Bair E. Ankyloglossia: incidence and associated feeding difficulties. *Arch Otolaryngol Head Neck Surg*. 2000;126(1):36–39
- do Rêgo Barros de Andrade Fraga M, Azoubel Barreto K, Barbosa Lira TC, Aparecida de Menezes V. Is the occurrence of ankyloglossia in newborns associated with breastfeeding difficulties? *Breastfeed Med*. 2020;15(2):96–102
- Schlatter SM, Schupp W, Otten J-E, et al. The role of tongue-tie in breastfeeding problems—a prospective observational study. *Acta Paediatr*. 2019;108(12):2214–2221
- Odom EC, Li R, Scanlon KS, Perrine CG, Grummer-Strawn L. Reasons for earlier than desired cessation of breastfeeding. *Pediatrics*. 2013;131(3):e726–e732
- Ahluwalia IB, Morrow B, Hsia J. Why do women stop breastfeeding? Findings from the Pregnancy Risk Assessment and Monitoring System. *Pediatrics*. 2005;116(6):1408–1412
- Li R, Fein SB, Chen J, Grummer-Strawn LM. Why mothers stop breastfeeding: mothers' self-reported reasons for stopping during the first year. *Pediatrics*. 2008;122(Suppl 2):S69–S76
- Dewey KG, Nommsen-Rivers LA, Heinig MJ, Cohen RJ. Risk factors for suboptimal infant breastfeeding behavior, delayed onset of lactation, and excess neonatal weight loss. *Pediatrics*. 2003;112(3 Pt 1):607–619
- Wallace H, Clarke S. Tongue tie division in infants with breast feeding difficulties. *Int J Pediatr Otorhinolaryngol*. 2006;70(7):1257–1261
- Notestine GE. The importance of the identification of ankyloglossia (short lingual frenulum) as a cause of breastfeeding problems. *J Hum Lact*. 1990;6(3):113–115

35. Livingstone VH, Willis CE, Abdel-Wareth LO, Thiessen P, Lockitch G. Neonatal hypernatremic dehydration associated with breast-feeding malnutrition: a retrospective survey. *CMAJ*. 2000;162(5):647–652
36. Dennis CL, Jackson K, Watson J. Interventions for treating painful nipples among breastfeeding women. *Cochrane Database Syst Rev*. 2014;2014(12):CD007366
37. Flaherman VJ, Schaefer EW, Kuzniewicz MW, Li SX, Walsh EM, Paul IM. Early weight loss nomograms for exclusively breastfed newborns. *Pediatrics*. 2015;135(1):e16–e23
38. World Health Organization. WHO growth standards are recommended for use in the United States for infants and children 0 to 2 years of age. Available at: https://www.cdc.gov/growthcharts/who_charts.htm#The%20WHO%20Growth%20Charts. Accessed May 17, 2022
39. Jensen D, Wallace S, Kelsay P. LATCH: a breastfeeding charting system and documentation tool. *J Obstet Gynecol Neonatal Nurs*. 1994;23(1):27–32
40. Matthews MK. Assessments and suggested interventions to assist newborn breastfeeding behavior. *J Hum Lact*. 1993;9(4):243–248
41. Hazelbaker A. *Tongue-Tie, Morphogenesis, Impact, Assessment, and Treatment*. Aidan and Eva Press; 2010:136–139
42. Amir LH, James JP, Donath SM. Reliability of the Hazelbaker assessment tool for lingual frenulum function. *Int Breastfeed J*. 2006;1(1):3
43. Ingram J, Johnson D, Copeland M, Churchill C, Taylor H, Emond A. The development of a tongue assessment tool to assist with tongue-tie identification. *Arch Dis Child Fetal Neonatal Ed*. 2015;100(4):F344–F348
44. Martinelli RLC, Marchesan IQ, Berretin-Felix G. Lingual frenulum protocol with scores for infants. *Int J Orofacial Myology*. 2012;38:104–112
45. Kotlow LA. Diagnosing and understanding the maxillary lip-tie (superior labial, the maxillary labial frenum) as it relates to breastfeeding. *J Hum Lact*. 2013;29(4):458–464
46. Srinivasan A, Al Khoury A, Puzhko S, et al. Frenotomy in infants with tongue-tie and breastfeeding problems. *J Hum Lact*. 2019;35(4):706–712
47. Francis DO, Krishnaswami S, McPheeters M. Treatment of ankyloglossia and breastfeeding outcomes: a systematic review. *Pediatrics*. 2015;135(6):e1458–e1466
48. Kotlow L. Diagnosis and treatment of ankyloglossia and tied maxillary frenum in infants using Er:YAG and 1064 diode lasers. *Eur Arch Paediatr Dent*. 2011;12(2):106–112
49. Kendall-Tackett K, Walker M, Watson Genna C. United States Lactation Consultant Association. *Tongue-Tie, Expert Roundtable, Clinical Lactation Monograph Series*. Praeclarus Press; 2018:106–107
50. O'Connor ME, Gilliland AM, LeFort Y. Complications and misdiagnoses associated with infant frenotomy: results of a healthcare professional survey. *Int Breastfeed J*. 2022;17(1):39
51. Bhandarkar KP, Dar T, Karia L, Upadhyaya M. Post frenotomy massage for ankyloglossia in infants-does it improve breastfeeding and reduce recurrence? *Matern Child Health J*. 2022;26(8):1727–1731
52. Hawk C, Minkalis A, Webb C, Hogan O, Vallone S. Manual interventions for musculoskeletal factors in infants with suboptimal breastfeeding: a scoping review. [Published online December 12, 2018] *J Evid Based Integr Med*. 2018;23:2515690X18816971
53. Dollberg S, Botzer E, Grunis E, Mimouni FB. Immediate nipple pain relief after frenotomy in breastfed infants with ankyloglossia: a randomized, prospective study. *J Pediatr Surg*. 2006;41(9):1598–1600
54. Berry J, Griffiths M, Westcott C. A double-blind, randomized, controlled trial of tongue-tie division and its immediate effect on breastfeeding. *Breastfeed Med*. 2012;7(3):189–193
55. Emond A, Ingram J, Johnson D, et al. Randomized controlled trial of early frenotomy in breastfed infants with mild-moderate tongue-tie. *Arch Dis Child Fetal Neonatal Ed*. 2014;99(3):F189–F195
56. Buryk M, Bloom D, Shope T. Efficacy of neonatal release of ankyloglossia: a randomized trial. *Pediatrics*. 2011;128(2):280–288
57. Santa Maria C, Aby J, Truong MT, Thakur Y, Rea S, Messner A. The superior labial frenulum in newborns: what is normal? [Published July 12, 2017] *Glob Pediatr Health*. 2017;4:2333794X17718896
58. Ghaheri BA, Cole M, Fausel SC, Chuop M, Mace JC. Breastfeeding improvement following tongue-tie and lip-tie release: a prospective cohort study. *Laryngoscope*. 2017;127(5):1217–1223
59. Pransky SM, Lago D, Hong P. Breastfeeding difficulties and oral cavity anomalies: the influence of posterior ankyloglossia and upper-lip ties. *Int J Pediatr Otorhinolaryngol*. 2015;79(10):1714–1717
60. Benoiton L, Morgan M, Baguley K. Management of posterior ankyloglossia and upper lip ties in a tertiary otolaryngology outpatient clinic. *Int J Pediatr Otorhinolaryngol*. 2016;88:13–16
61. Nakhash R, Wasserteil N, Mimouni FB, Kasirer YM, Hammerman C, Bin-Nun A. Upper lip tie and breastfeeding: a systematic review. *Breastfeed Med*. 2019;14(2):83–87
62. Shah S, Allen P, Walker R, Rosen-Carole C, McKenna Benoit MK. Upper lip tie: anatomy, effect on breastfeeding, and correlation with ankyloglossia. *Laryngoscope*. 2021;131(5):E1701–E1706
63. Nurture and Nourish Services. Available at: <https://nurturenourishservices.com/>. Accessed April 22, 2024
64. Wong K, Patel P, Cohen MB, Levi JR. Breastfeeding infants with ankyloglossia: insight into mothers' experiences. *Breastfeed Med*. 2017;12(2):86–90
65. Dixon B, Gray J, Elliot N, Shand B, Lynn A. A multifaceted program to reduce the rate of tongue-tie release surgery in newborn infants: Observational study. *Int J Pediatr Otorhinolaryngol*. 2018;113:156–163
66. Caloway C, Hersh CJ, Baars R, Sally S, Diercks G, Hartnick CJ. Association of feeding evaluation with frenotomy rates in infants with breastfeeding difficulties. *JAMA Otolaryngol Head Neck Surg*. 2019;145(9):817–822
67. Edmunds JE, Fulbrook P, Miles S. Understanding the experiences of mothers who are breastfeeding an infant with tongue-tie: a phenomenological study. *J Hum Lact*. 2013;29(2):190–195
68. Ricke LA, Baker NJ, Madlon-Kay DJ, DeFor TA. Newborn tongue-tie: prevalence and effect on breastfeeding. *J Am Board Fam Pract*. 2005;18(1):1–7
69. de Almeida Brandao C, De Waele Souchois deMarsillac M, Barja-Fidalgo F, et al. Is the Neonatal Tongue Screening Test a reliable and valid tool for diagnosing ankyloglossia in newborns? *Int J Paediatr Dent*. 2018;28:380–389